

CAN AN IMPERFECT PEELING IN MACULAR TRACTIONAL SYNDROME GIVE A GOOD VISUAL RESULT IN SELECTED CASE ? OUR EXPERIENCE

NICOLETTI G.A., SCALIA G.

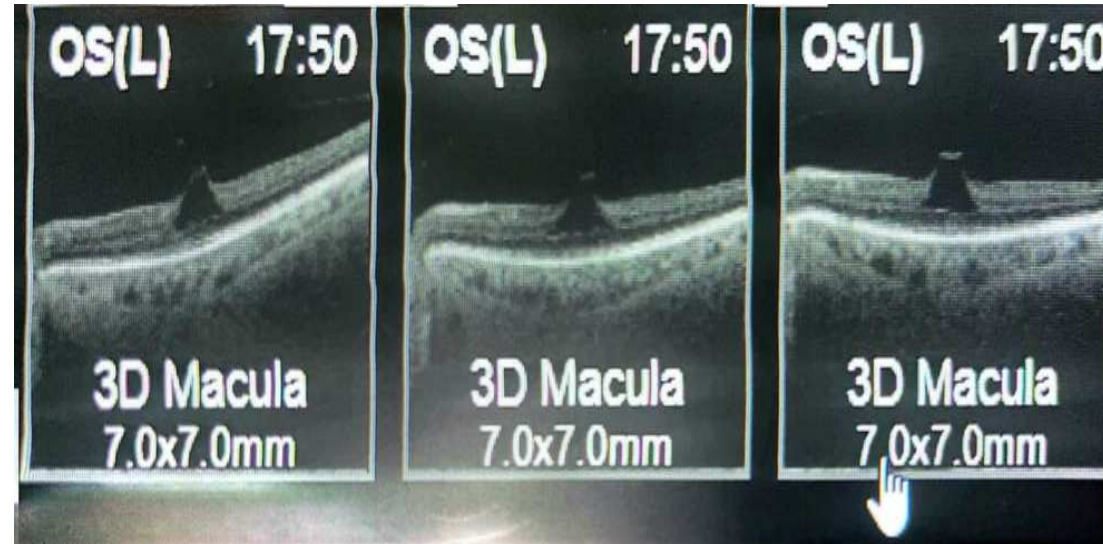
**P.O. S. MARTA E S. VENERA, ACIREALE-ASP
CATANIA**

PATIENT: V.C.

OCT pre-op

FEMALE

AGE 78 y.o.



RADIOTHERAPY AFTER SURGERY FOR TONGUE AND
SALIVARY GLANDS ADENOCARCINOMA WITH METASTASIS ON
SUBMANDIBULAR LYPH NODES (TN2)

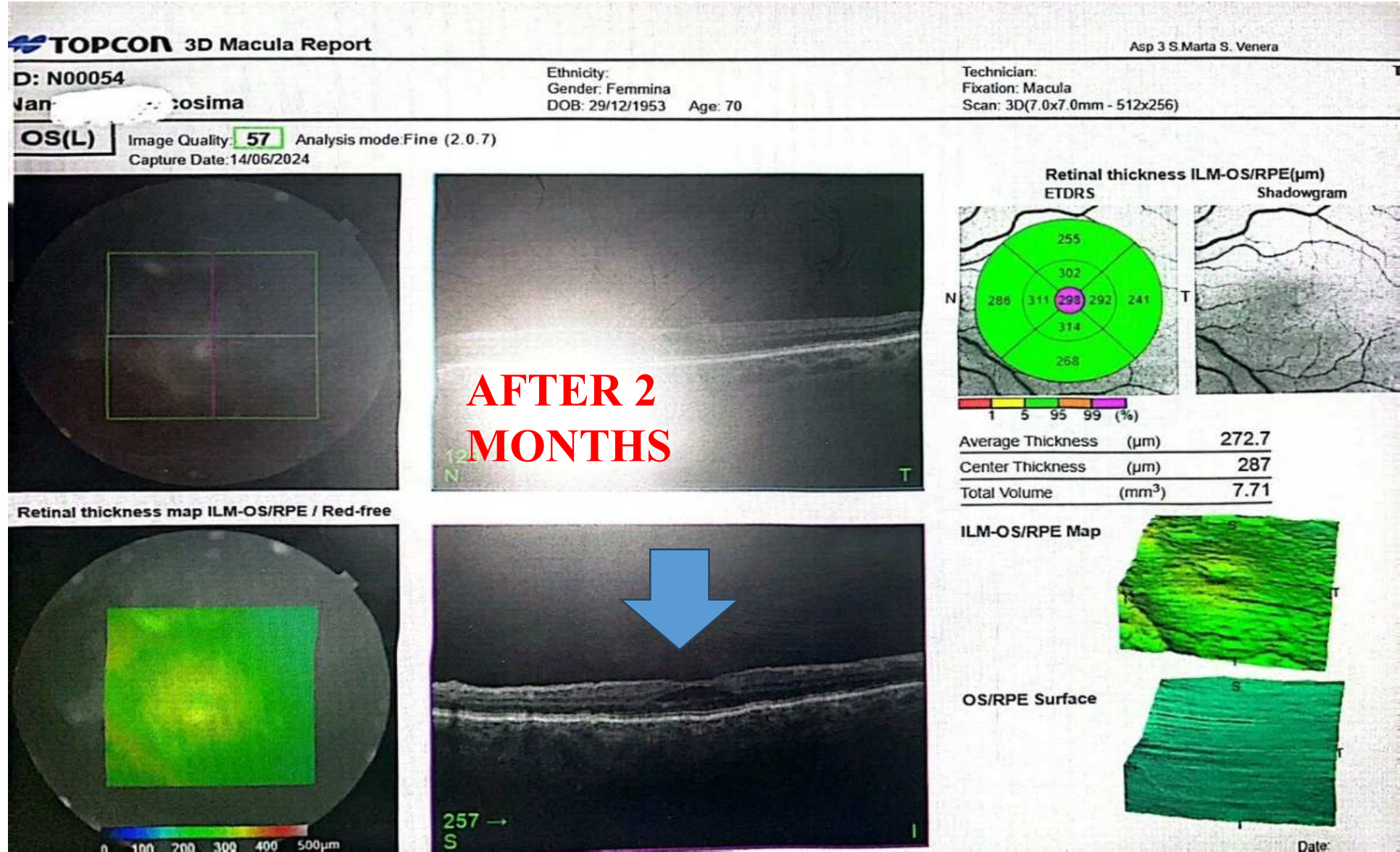
- MACULAR PUCKER + VITREO - MACULAR TRACTIONAL
SYNDROME (SVTM) IN OSX and SUBCAPSULAR CATARACT, BCVA
1/10 (Snellen)

INCREASED RISK OF SURGICAL COMPLICATIONS !!!

(LITERATURE)

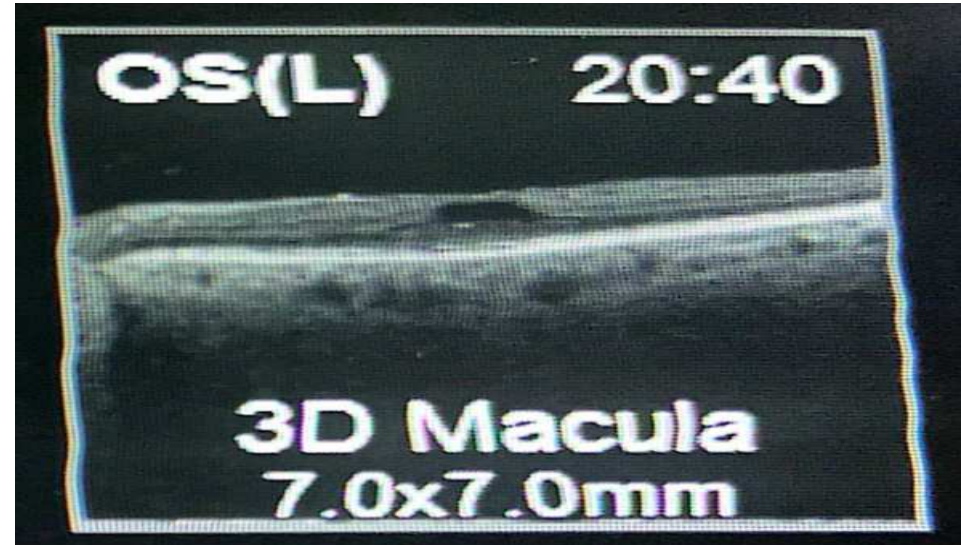- MACULAR HOLE DURING OR AFTER SURGERY in VITREO-
MACULAR TRACTION (SVTM) :
- 5 % Stalmans, 2016
- 11% Wakebayashy e coll., 2023 MIOPH +++
- 20% Jairath e coll., 2022 23G >>25gG

POST-OPERATIVE RESULTS...



POST-SURGERY RESULTS

- BCAV (after 3 months) 9/10 (Snellen) cyl -1,75 axis 90°
- OCT signs (after 3-4 months)
 - significant RCT reduction
(retinal central thickness)
 - Macular profile restoration
- Lamellar internal macular hole (MH) development,
probably caused by macular stress traction....



CONCLUSIONS

- THESE SURGERY RESULTS ARE LUCKY OR RANDOM ??
- IT' BETTER IN SELECTED CASES (STRONG ADHESION AND LARGE AREA OF TRACTION) TO LEAVE A RESIDUAL OF MER / HYALOID, WITHOUT TANGENTIAL AND PERPENDICULAR TRACTIONS ON THE MACULA ??
- IT COULD BE SAFER ???
- IT MEANS:
 - LOW RISK OF IATROGENIC MACULAR HOLE (MH)
 - BETTER PROBABILITY OF INCREASE POST-OPERATIVE BCVA !!

THANK YOU FOR YOUR
ATTENTION !

